

Ministry of Public Health of Russian Federation

RUSSIAN CARDIOLOGICAL
SCIENTIFIC AND PRODUCTION COMPLEX

Applying CardioVisor-06c™

in screening examinations

Method of dispersion plotting

Doctors' manual

Moscow
2004

Applying CardioVisor –06c in screening examination
Method of dispersion plotting

The manual is intended for cardiologists
and specialists in functional diagnosis.
Prepared and printed in Section of new
diagnosis methods, RCSPC, Ministry of
Public Health of Russia

Authors : Prof. G.V. Ryabykina, DM,
A.S. Sula, Ph. D.

Developer : Russian cardiological science and production
complex

ANNOTATION

This manual presents the main principles of operation of CardioVisor – 06c designed for screening examination and describes the principles of analyzing ECG low amplitude dispersion variations. The authors discuss characteristics of the formation of dispersion functions used for quantitative estimation of ECG low amplitude variation parameters, consider principles of forming visual image of dispersion functions in shape of the so-called dispersion portrait of the heart and give grounds for using this device. They also cite examples of using CardioVisor-06c for revealing myocardial ischemia and control of dynamics.

The sensitivity and specificity of the method of analysis are estimated on 192 patients. The estimation is made for the variant of diagnosing any kind of pathology in screening examinations and for the variant of diagnosing only ischemic heart disease. The authors show that sensitivity of dispersion functions in differentiating norm and pathologies in many cases is higher than sensitivity of the usual ECG analysis.

Abbreviations

ACS	- aortocoronary shunting
BMA	- blunt margin artery
DA	- diagonal artery
DP	- dispersion plotting
IHD	- ischemic heart disease
MI	- myocardial infarction
ITM	- informative topological model
CAG	- coronary angiography
EDD	- end diastolic distantia
ESD	- end systolic distantia
LV	- left ventricle
LA	- left auricle
MV	- millivolt
CA	- circumflex artery
RV	- right ventricle
RA	- right auricle
APD	- anteroposterior distantia
PICS	- postinfarction cardiosclerosis
AIA	- anterointerior artery
TPWLV	- thickness of the posterior wall of the left ventricle
TIVS	- thickness of the interventricular septum
EF	- ejection fraction
LVH	- hypertrophy of the left ventricle

1. Introduction

The classical method of analysis of ECG at rest due to its simplicity and methodological completion remains most acceptable and widely used in all spheres of cardiagnosis. However, despite considerable improvement of the modern ECG analysis and development of computer methods of analysis of ECG signals, two problems of analysis of ECG at rest are still actual, namely: low sensitivity and specificity to ischemic heart disease (IHD) and insufficient sensitivity for individual prognosis estimation of risk after myocardial infarction (MI) or other states endangering life. In recent years the urgency of these problems has been growing as against the background of growing statistic indexes of spreading IHD, the ECG method remains the only means accessible in mass prophylactic medical examination of the population. The existing system of ambulatory and clinic cardiological examination in many cases does not manage to ensure timely beginning of therapeutic and reanimating measures in case of heart attack. Unexpected occurrence of heart pathology in people who before this episode were considered healthy become more often and often. One of the methods of preventing acute cardiological states is using accurate screening ECG technologies for operative and reliable identification of people with a high risk of pathological changes in the myocardium. Such technologies should ensure detailed and frequent control of dynamics of the heart which will make it possible to timely detect symptoms of pathology at the pre-hospital stage or to see development of negative tendencies at the very early stages in hospital treatment.

CardioVisor-06c is designed just for this application. This is the first serial device on the market of modern computer ECG analyzers based not on the analysis of usual ECG characteristics but on technology of calculation and

three-dimension visualization of the electromagnetic radiation of the myocardium by parameters of amplitude dispersion of the standard ECG signal from extremities (4 electrodes, Patent DE 199 33 277 A1).

In conditions of the infrastructure of cardiological service of the Russian Federation this device is fairly effective for overcoming the above two disadvantages of the ECG method for the following reasons:

- 1) mean time of examination of one patient does not exceed 1...3 minutes including the time of applying electrodes,
- 2) the procedure of examination (especially when the patient comes for medical aid for the first time) can be completed without putting off clothes, in sitting position; with a portative set of the instrument examination can be completed right at the place of hospitalization or at the working place in screening examinations,
- 3) the sensitivity of the device to ischemic changes in the myocardium is not less than 80% with specificity not lower than 63%,
- 4) the sensitivity of the instrument to pathological changes with control of dynamics is not less than 95% with specificity not lower than 90%.

It is expected that as a result of ambulatory use of CardioVisor-06c in the framework of cardiological service 50% of cardiopathologies from the group of acute and urgent manifestations can come over to the group of controlled manifestations undergoing timely prophylactic therapy. This, in its turn, will increase the effectiveness of the entire cardiological service.

2. Indications and contraindications for applying the instrument

Indications for applying CardiVisor-06c are as follows:

- 1) periodical ambulatory examination in mass prophylactic examination of the population for early detection of pathology at the pre-clinical stage,
- 2) necessity of estimating the presence of pathological changes in the myocardium when the patient comes for medical aid for the first time,
- 3) necessity of estimating dynamics of myocardial changes in the course of treatment.

As the basis of the procedure is ECG from the leads from extremities there are no contraindications for applying the device.

3. Software of the method

CardioVisor-06c is computer cardioanalyzer EC9D-01-KARD (registration certificate #29/02020503/56-5803 dated 20.11.2003, OOO Medical Computer Systems, Moscow, Zelenograd) and software. It is supplied complete with import ECG electrodes for limbs. Connecting with the computer is made through interface USB. The software is intended for operation with computers with Microsoft operation system Windows-98, Windows-2000, and Windows-XP.

4. Description of the method of analysis used in the device

The principle of operation is based on the new method of analysis of casual low amplitude fluctuations of the ECG signal [1,2] - ECG dispersion plotting. ECG DP method is based on the informative topological model of small ECG fluctuations - ECG ITM. The main algorithm procedures of the ECG DP method is based on the following.

The multiplicity of control effects and variability of receptor signals determining electrochemical phenomena in depolarization-repolarization processes of the myocardium inevitably leads to small casual ECG fluctuations with each contraction of the heart even in the state of physiological norm. The amplitudes of these fluctuations (dispersion of fluctuations) according to the authors' data do not exceed 0.01...0.03 mV, i.e. they are several tens of times smaller than amplitudes of ECG peaks. The term "dispersion" corresponds to the generally accepted definition of difference between the maximal and minimal values of the varying quantity. In order to observe and measure the characteristics of such casual fluctuations it is necessary to plot the signals of ECG one-type peaks, i.e. synchronize the beginning of electric excitation of several successive peaks. Fig.1 and Fig.2 give examples of such low amplitude QRST fluctuations in one of the leads. Fig. 1 shows ECG low amplitude fluctuations of a healthy person, Fig.2 - in case of sub-acute stage of MI. In the cited cases one can see some characteristic amplitude and frequency peculiarities of changing fluctuations.

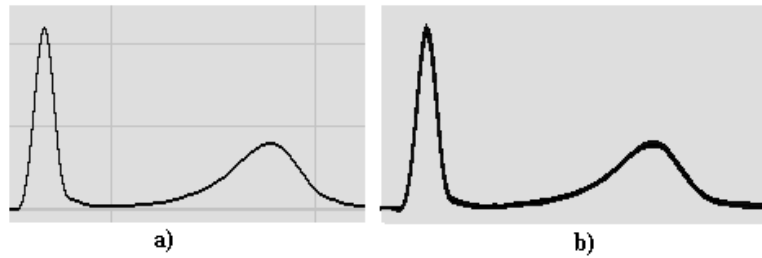


Fig1. ECG low amplitude fluctuation in successive QRST complexes of a healthy heart.

a) single complex; b) 7 successive synchronized complexes

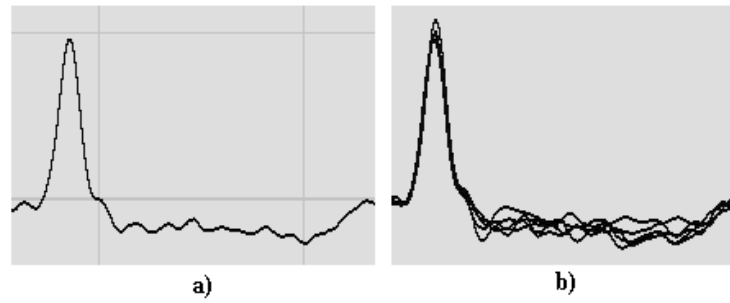


Fig. 2. ECG low amplitude fluctuation in successive QRST complexes with MI.

a) - single complex; b) 7 - successive synchronized complexes

Regularities of variation of such fluctuations due to insignificance of the amplitude and casual nature were not studied in the generally accepted methods of ECG analysis. With the beginning and development of myocardial pathology dispersion characteristics begin to change earlier than ECG peaks. Therefore with control of dispersion characteristics it is possible to obtain information about developing pathology with forestalling. It is this principle that is used in CardioVisor-06c to raise sensitivity of the ECG analyzing technique under consideration to pathological changes. The unique peculiarity of dispersion characteristics is their high specificity in differentiation of norm-pathology states, i.e. CardioVisor-06c does not detect

pathology in cases where there is no pathology. Dispersion characteristics in CardiooVisor-06c are calculated by 9 groups of dispersion deviations : G1 – depolarization of the right auricle, G2 – depolarization of the left auricle, G3 – depolarization of the right ventricle, G4 – depolarization of the left ventricle, G5 – repolarization of the right ventricle, G6 – repolarization of the left ventricle, G7 – symmetry of depolarization of the ventricles, G8 – interventricular blocks, G9 – ventricular hypertrophy. Groups G1-G7 analyze a wide class of dispersion changes corresponding to many clinic pathologies. The names of these groups reflect first of all the electrophysiological characteristics of changes in the myocardium of auricles and ventricles (derepolarization processes). On the contrary, groups G8 and G9 characterize highly specific dispersion changes corresponding to blocks and hypertrophies. The names of the latter two groups practically coincide with corresponding diagnoses. Dispersion characteristics corresponding to an individual group of deviations are presented as time functions characterizing averaged amplitude variations in individual spaces of cardiointerval. Differentiation of norm and pathology was made on the basis of the standard training procedure for automatic classifier on a control group of healthy people and a group of people with strictly verified clinic diagnoses. This group included IHD without scars, IHD with scars, IHD against the background of HLV, intraventricular blocks, auricular fibrillation, IHD after ACS and transplantation, HLV and aortomitral diseases, HLV against the background of endocrinometabolic changes, hypertrophic cardiomyopathy, combined ventricular hypertrophy (congenital and acquired heart diseases). For dispersion lines in each group of analysis (G1-G9) were formed the limits of the norm. Fig.4 shows an example of two dispersion lines in groups G3 and G4. The horizontal axis in these examples corresponds to 20 time moments of

“averaged” QRS complexes. The vertical axis corresponds to mean amplitudes of variation of surface potentials in successive QRS complexes. Dispersion lines 1 and 2 correspond to different localization of the myocardial regions giving rise to these dispersion changes in depolarization process. For instance, for group G4 the dispersion line corresponds to the posteroleft section of LV, while dispersion line 2 corresponds to the anteroright section of LV. The upper limit of the norm is red, the lower limit is green. If there are no pathological changes, the dispersion line (blue) will lie between the limits.

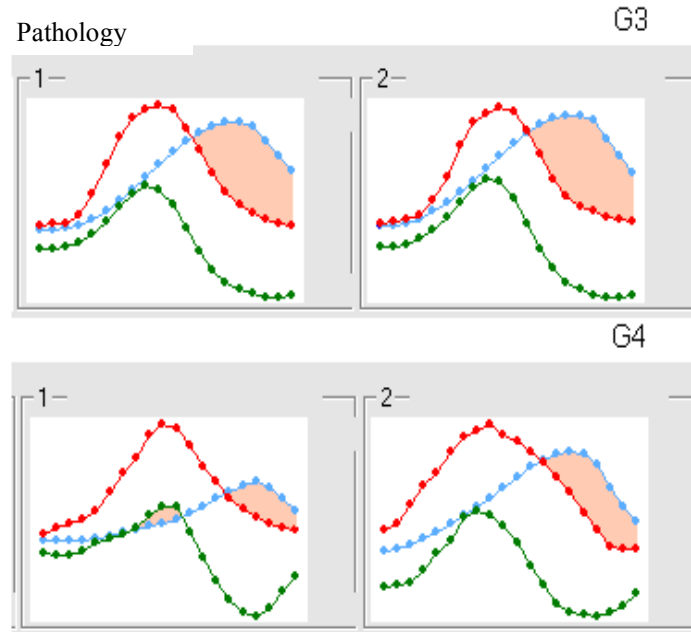


Fig.4. Example of changes in dispersion functions (1,2) in groups G3 and G4 in case of pathology. Orange signifies the area reflecting the value of deviation from the norm.

Dispersion lines are highly sensitive to myocardial changes, therefore there are practically no patients with

absolutely the same dispersion characteristics. However, for practical purposes in each group (G1-G9) sensitivity is reduced so as to differentiate from 10 to 30 kinds of dispersion lines. This turned to be sufficient for effective differentiation of norm and pathology. If there are significant pathological changes, the corresponding dispersion lines overstep the upper or the lower limits of the norm (Fig.4). The above operations with groups G1...G9) are internal operations of the classifier of the device. In Fig.4 the regions of overstepping the limits are colored orange. The larger the area of these regions, the bigger the deviation from the norm. Integral indicator «Myocardium» estimates the value of this area, i.e., the expressiveness of deviations .

“*Myocardium*” changes in a relative range from 0% to 100%. “*Myocardium*” = 0% corresponds to absolute absence of any significant deviations, i.e. all dispersion lines are within the limits of the norm. The bigger the indicator value, the bigger the deviation from the norm. “*Myocardium*” = 100% corresponds to pathology relating to *distinct deviations from all the groups of dispersion characteristics*. For instance, for a considerable number of cases of distinct clinical picture of IHD the value of this indicator is 40...80%, while in the absence of clinically significant changes “*Myocardium*” varies from 0% to 14%.

Output information about dispersion changes is shown on the screen of display and consists of two groups of data: the so-called “*portrait of the heart*”, including computer reconstruction of dispersion deviations on the surface of the “*quasi-myocardium*” (i.e. 3-dimentional reconstruction of the epicardium), and messages including the conclusion and recommendations for the doctor.

The portrait of the heart is “a snap-shot” obtained on the screen of display as a result of visualization of calculated mean dispersion characteristics of low amplitude

fluctuations of the registered ECG. *The portrait of the heart* is given in two forms : from the side of the right auricle and the right ventricle (Fig.5) and the sight from the side of the left auricle and the left ventricle (Fig.6) These two sights do not correspond to the natural anatomic location of the heart in the thorax. In order to see the largest area of the epicardial surface of each auricle and ventricle in the portrait of the heart the computer 3-dimensional model of the heart is artificially rotated top backward around the vertical axis V and at a small angle clockwise around the longitudinal axis L (sight from the top). In visual scanning of the portrait this considerably increases the observed area of RA and RV. Similar rotation in Fig.6 increases the observed area of LA and LV.

The portrait of the heart in the ventricular region reflects the integral picture of dispersion changes calculated both for depolarization and for repolarization of the myocardium. Dispersion changes in the portrait in the auricular region correspond to the depolarization phase. The color of the portrait changes both with deviations of the amplitude of dispersion characteristics and with a change in retarding or advancing dispersion characteristics regarding time (dispersion characteristics phases), which correlate with values of intervals P – Q, Q – T, and QRS. The location of amplitude and phase color indicators in a heart portrait is given in Fig.5 and Fig.6. The amplitude indicators are in the corresponding anatomic regions of the quasi –epicardium of the portrait : RA, RV, LA and LV.

The location of phase indicators approximately reflects the projection of the final stages of the corresponding front of depolarization on “the quasi-epicardium” of the portrait of the heart. For instance, indicator 3 reflecting rhythm regularity conventionally is in the region of location of the sinus node. In spite of the conventionality of the anatomic location of phase dispersion indicators reflecting changes in intervals P – Q,

Q-T and QRS, these indicators ensure quick and integral perception of dispersion changes in temporal characteristics of the cardiac cycle.

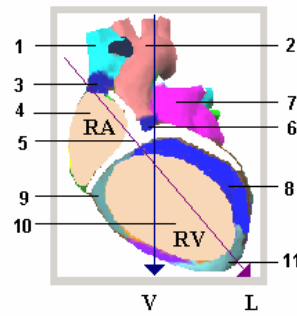


Fig.5. Visual structure of the right sections of the heart

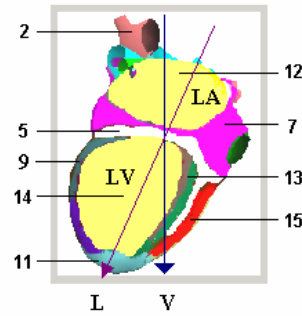


Fig.6. Visual structure of the left sections of the heart.

v - vertical axis of the heart

L – longitudinal axis of the

- 1 - vena cava superior
- 2 - aorta
- 3 - rhythm integral indicator
- 4 - indicator of the state of RA myocardium (depolarization dispersion)
- 5 - indicator of P-Q interval anomalies
- 6 - indicator of stability of AB-conduction
- 7 - integral indicator of the state of two auricles (general characteristics conditioned by common source of excitation)
- 8 - indicator of final phase of RV depolarization (projection in the region of the interventricular septum)
- 9 - indicator of ventricular repolarization duration (correlates with Q – T)
- 10 - indicator of state of RV myocardium (repolarization dispersion)
- 11 - indicator of ventricular depolarization duration (QRS duration)
- 12 - indicator of state of LV myocardium (repolarization dispersion)
- 13 - indicator of final phase of LV depolarization
- 14 - indicator of state of LV myocardium (repolarization dispersion)
- 15 - indicator of final phase of RV depolarization (projection on posterior wall)

The expressiveness of changes is determined by the changing color of “quasi-epicardium” which in the norm is even green. With different deviations from the norm the color in the region of changes turns to yellow or red. The larger the red area of the “quasi-epicardium”, the higher the expressiveness of deviation. When dispersion changes are combined with large positive amplitudes of repolarization of ventricular myocardium (ECG pointed T tooth) the red of corresponding sections of the “quasi-epicardium” acquires a purple hue. Dispersions corresponding to pathological inversion of tooth T in ECG as a rule are red.

Messages include three main groups of data: integral indicators, conclusion and details. The text of the conclusion contains information about the presence of pathological changes and recommendations for further actions (inexpedience or necessity of complete cardiological examination, control of dynamics, etc.). The text of detailing gives information about the sort of probable pathologies, which can be detected during subsequent complete examination.

Fig. 7 cites examples of a heart portrait of a healthy person and a portrait of a heart with pathological changes.

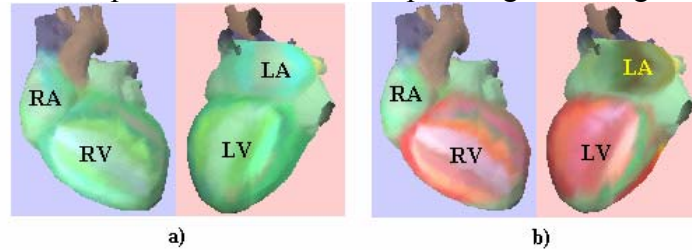


Fig.7. Examples of heart portraits. a) - norm, b) - IHD, PICS, diabetes mellitus.

Fig.7b clearly shows myocardial changes in LA, LV and RV. The red strip in region 15 and LV colored red are the signs of high probability of IHD. The pink sections in regions 5 and 9 which correspond to phase dispersion

indicators are evidence of a significant increase in the length of intervals Q-T and P-Q.


4.1. Peculiarities of control of ischemic myocardial changes

CardioVisor –06c is highly sensitive to any changes of metabolic, neurogenetic and humoral nature. Therefore methods of practical application of CardioVisor –06c in control of myocardial ischemia must maximally facilitate differentiation of primary hypoxia caused by coronary insufficiency from hypoxia of another genesis (chronic pulmonary pathology, anemia, diabetes, etc.). Besides, in 24 hours the oxygen balance undergoes numerous changes both in IHD patients and in healthy people [4]. For this reason maximally accurate analysis of early indistinct symptoms of ischemia necessitates that the following three groups of factors be considered:

- Firstly, monitoring daily rhythm of ischemia variability [5]. If it is necessary to elicit ischemic changes, especially transient changes, in a most sensitive way, it is expedient to perform examination in the period from 9:00 a.m. to 11:00 a.m. and from 6:00 p.m. to 8:00 p.m.
- Secondly, monitoring differences in the time of return of the myocardium to the initial state after a short-time hypoxia in IHD patients and healthy people. To elicit this factor it is sufficient to raise the pulse* by 15...25% by simple means (squatting, running on the spot, etc.) and after this episode to take successively 2-3 portraits of the heart.
- Thirdly, monitoring clinic data about recurrent myocardial changes as a result of endocrinoelectrolytic and other metabolic changes.



The main criteria of the presence of clinically significant ischemic changes are the following factors :

- appearance of red coloring in the portrait of the left ventricle (regions 13,14, 15 in Fig.6) and simultaneous rise of the value of the indicator “Myocardium” above 18;
- information about probable ischemia in the text of the conclusion in the section “Ventricles”;
- text information about probable ischemia simultaneously in groups G3, G4, G7 in “Detailing” (button )

If there is text information about ischemia but region 15 in the portrait is green, IHD is hardly probable. Such cases correspond to pathological changes of another genesis which are not differentiated by the device (most often these are cardiomyopathy and myocarditis). Messages about ischemic changes in other sections of the conclusion and detailing supplement and specify the main information.

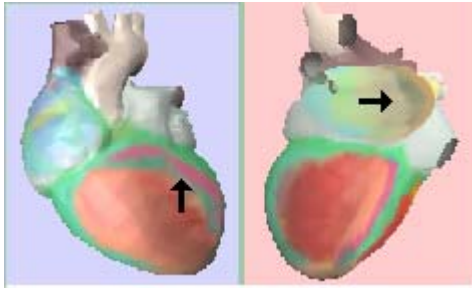
* This raise is permissible only if there is no distinct tachycardia.



Drugs can affect the sight of the portrait and screening estimation. If the device is used in the course of treatment it is necessary to compare the current heart portraits with those obtained before the beginning or at the beginning of drug therapy.

Let us consider some examples of heart portraits in fresh infarctions.

1 **Patient 1. Diagnosis:** Acute myocardial infarction of one week, posterolateral localization. EchoCG: EDD –6.3, ESD – 4.3, TPWLV – 1.2. Hypokinesis of posterior wall, myocardial infarction of the lateral wall, enlarged LA.



CardioVisor-06c
output data :
Myocardium: 61%,
Pulse : 59,
electric axis –
normal position.

General conclusion
:

“Distinct deviations from norm: See probable detailing by deviation groups. If these deviations are observed for the first time and at present are permanently recurrent in successive heart portraits – IMMEDIATE examination is necessary! Probable ISCHEMIC changes in ventricular myocardium – complete examination is necessary. Changes in auricular depolarization”.

Rhythm: *“Pulse –norm, enlarged rhythm indicator is conditioned by high STRESS: NO clear symptoms of arrhythmia. Low indicators of rhythm variability: sign of EXPRESSED TENSION of rhythm regularity system. Follow dynamics.”*

Auricles : *“ Typical changes in auricular repolarization which can accompany probable ischemic changes in the left ventricle”.*

Ventricles: *“Possible ISCHEMIC changes in ventricular myocardium –complete examination is necessary. Probable ISCHEMIC changes in ventricular myocardium –complete examination is NECESSARY. These symptoms can correlate with FOCAL CHANGES in myocardium. Probable localization of ventricular myocardium changes:*

POSTERIOR wall or basal segment of septum. For precise determination of localization complete examination is necessary. MODERATE increase in QRS length."

Ventricular hypertrophy: "Indistinct combined asymmetry of ventricular depolarization."

Detailing text: G1 – "Signs of enlarged left auricle. Distinct repolarization change-often correlates with distinct ischemia of left ventricle." G4 – "Distinct retard of left ventricle depolarization with domination in lateral and anterolateral sections. Distinct ischemia. Often observed in fresh myocardial infarctions." G7 – "Distinct changes in symmetry of ventricular excitation, changes in S-T. Distinct signs of ischemia, scar changes cannot be excluded".

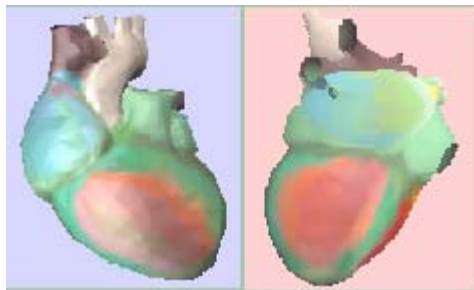
The **portrait of the heart** shows typical ischemic signs in both ventricles and changes in LA (marked by arrow) which often accompany LV ischemia. ECG of this examination is shown in Fig.8.

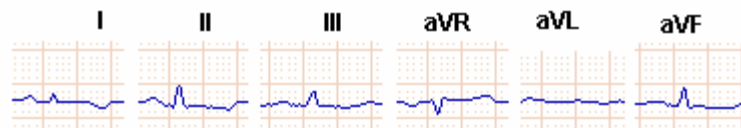

Fig. 8

COMMENTS: obvious ischemia. If this state is revealed for the first time – urgent examination is necessary to exclude possibility of MI.

[2] Patient 2. Diagnosis: Acute myocardial infraction of one week, Focal changes of anteroseptum, apical and inferior localization.



CardioVisor-06c
output data :
Myocardium: 52%,
Pulse : 62, electric
axis –normal.

General conclusion : “ Deviations from norm: See probable detailing by deviation groups. If these deviations are observed for the first time and at present are permanently recurrent in successive heart portraits – IMMEDIATE examination is necessary! Changes in ventricular myocardium – signs of possible ISCHEMIC changes. Minor CHANCES in auricular depolarization on the norm limit: Control of DYNAMICS to elicit tendencies of changes is expedient. Lengthened Q-T interval.”

Rhythm: “Pulse –norm. Enlarged rhythm indicator is conditioned by high STRESS: NO clear symptoms of arrhythmia. Low indicators of rhythm variability: sign of EXPRESSED TENSION of rhythm regularity system. Follow dynamics.”

Ventricles: “Possible ISCHEMIC changes in ventricular myocardium –complete examination is necessary. Probable ISCHEMIC changes in ventricular myocardium or temporal transient myocardial ischemia. These symptoms can correlate with coronary changes – stenocardia is possible. Probable localization of ventricular myocardium changes: POSTERIOR wall or ANRETROSEPTUM wall. For precise determination of localization complete examination is necessary.”

Detailing text: G4 – “ Norm limits. Increases deviations close to norm. Follow tendencies.” G6 - Distinct repolarization changes – sign of ischemia. Inversion of potentials in all ventricular sections. If simultaneously there are deviations in G3-G4 – sign of ischemia.” G7 – “Distinct changes in the symmetry of vertices in depolarization process – signs of distinct ischemia. Sometimes correlates with scar changes”.

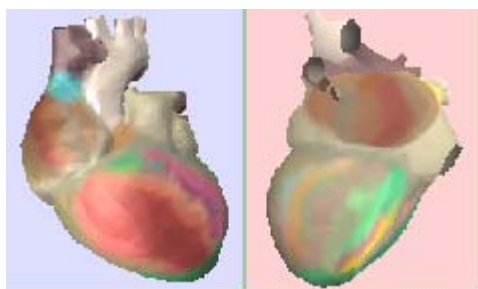
The **portrait of the heart** shows typical ischemic signs in both ventricles. ECG of this examination is shown in Fig.9.

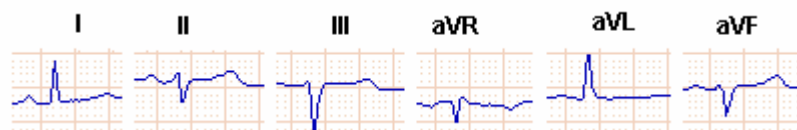

Fig. 9

COMMENTS: As Indicator *Myocardium* is of great value - obvious ischemia. If this state is revealed for the first time – urgent examination for differential diagnosis of MI is necessary.

3 Patient 3. **Diagnosis:** Acute myocardial infarction. Focal changes in anteroseptum localization. The portrait of the heart is obtained at the time of anginal attack.



CardioVisor-06c
output data :

Myocardium: 34%,

Pulse : 74,
electric axis –normal
position.

General conclusion : “*Deviations from norm: See probable detailing by deviation groups. If these deviations are observed for the first time and at present are permanently recurrent in successive heart portraits – IMMEDIATE examination is necessary! Changes in ventricular myocardium resembling ISCHEMIC changes. Control of dynamics and complete examination are expedient. Changes in auricular depolarization”. Lengthened Q-T interval. Considerable lengthening of Q-T with changes in ventricular repolarization. Control*

dynamics – these signs can correlate with possible RELAPSES of aggravation of symptoms.”

Auricles : “ *Probable auricular fibrillation.*”

Ventricles : “ *It is EXPEDIENT to control DYNAMICS as there are signs of CHANGES on the BORDER of norm which can be the beginning of ischemic changes in the myocardium or a transient episode of short-time ischemia.*”

Detailing text: G1 – “*Distinct decrease in depolarization potentials in all auricular sections. Often correlates with auricular fibrillation*”. G2 – “*Moderate inversion of depolarization potentials – sign of intermittent states fibrillation/palpitation . Often correlates with ischemia of left ventricle.*” In G5,G6 – *signs of obvious ischemia, but in G7 – uncertainty as in G7the signs are distinct but there are no simultaneous changes in G3 and G4.*

*The **portrait of the heart** shows typical changes resembling ischemia though there are no typical signs of distinct ischemia in region 15 (Fig.6)*

COMMENTS: As Indicator *Myocardium* is of great value - 34% - ischemia is probable. In the portrait there is no most characteristic sign of distinct ischemia in region 15, while the changes in the left ventricle are of mean intensity of anterior and lateral localization. However, these peculiarities do not exclude MI as indicator *Myocardium* is very large. These conclusions are also confirmed by the shape of ECG signal in Fig.10.

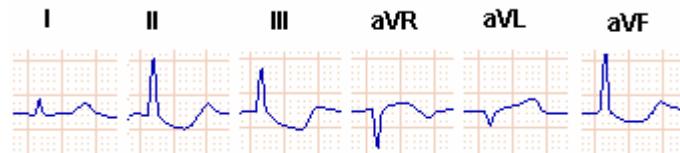
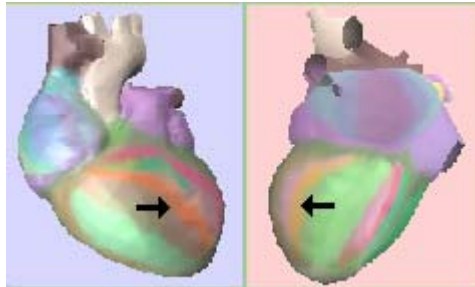


Fig. 10

The following example illustrates the peculiarities of the conclusion with hypertrophic cardiomyopathy.

4 *Patient 4. Diagnosis:* asymmetric hypertrophic cardiomyopathy with signs of obstruction of LV efferent tract. Chronic gastritis without aggravation. Primary manifestations of spreading vertebral osteochondrosis with musculotonic syndrome. ECG: clockwise rotation of the heart around longitudinal axis. Changes in auricular component with signs of enlargement of both auricles. Delay and insignificant failure of intraventricular conductivity. Voltage criteria of hypertrophy of the left ventricle. Possible IVS hypertrophy. EchoCG - the left auricle is considerably enlarged: 4.8x5.3 cm (LA in the norm –from 2.0 to 4.0 cm). Scintigrams show a decrease in pyrophosphate accumulation in lower and partly in lateral localization. Area and depth of damage correspond to peculiarities of HCMP.



CardioVisor-06c
output data :
Myocardium:
22%, Pulse: 70,
electric axis –
normal position.

General conclusion : *“DEVIATIONS from the norm: See probable detailing by deviation groups. If these deviations are observed for the first time and at present are permanently recurrent in successive heart portraits – control of dynamics is necessary and complete examination is expedient. Changes in auricular depolarization. Lengthened Q-T interval. Changes in ventricular myocardium resembling ISCHEMIC changes. Control of dynamics and complete examination are expedient.”*

Rhythm: *“Pulse –norm. Increased rhythm indicator is conditioned by high STRESS: NO obvious signs of arrhythmia. Low indicators of rhythm variability – sign of EXPRESSED TENSION in the rhythm regulatory system. Follow dynamics”.*

Auricles : *“Typical auricular repolarization changes which can accompany probable ischemic changes in the left ventricle. Signs of enlargement of the left auricle, probable moderate signs of hypertrophy of the left auricle.”*

Ventricles : *“ Probable signs of ISCHEMIC changes in ventricular myocardium – complete examination is expedient.”*

Ventricular hypertrophy: *“Minor ventricular asymmetry to the left ventricle as compared with the norm – possible primary signs of LV hypertrophy changes.”*

Detailing text: G1 – *“Increased depolarization potentials, expressed changes in repolarization. Moderate signs of DILATATION.”* G2 – *Increased potentials of depolarization, expressed changes in repolarization. Moderate signs of DILATATION. Often correlate with affected myocardium vessels.”* G5 – *“Expressed changes in repolarization. If there are expressed simultaneous changes in G3-G4 – obvious ischemia.”* G7 – *“Expressed asymmetry in ventricular depolarization at the primary stage to the left – sign of moderate ischemia. If expressed*

deviations are observed simultaneously in G3-G4 – distinct ischemia is probable.”

*The **portrait of the heart** besides considerable changes in the region of the anterior wall shows two narrow orange strips of changes close to IVS in both ventricles and purple changes in auricles, LA changes prevail*

COMMENTS: The current state corresponds to pathological changes (*Myocardium* above 19%), messages referring to probable myocardial ischemia and possible LV hypertrophy. However there are peculiarities which do not correspond to typical manifestations of ischemia in the portrait. *Firstly*, there are no characteristic red strip in region 15 in the left ventricle (Fig.6) *Secondly*, G5,G7 detailing messages state that the conclusion “ischemia” is probable only if G3,G4 simultaneously note expressed deviations. In the given case groups G3,G4 elicit no deviations. **Due to this the pathological character of the changes revealed is authentic but because of the above discrepancies these changes can be of non-ischemic origin. As at the same time there are signs of possible LV hypertrophy while the portrait shows changes in the IVS region (orange strips), differential diagnosis is necessary to discriminate IHD and cardiomyopathy. The indicator “Myocardium” in this case is not of very great value (under 23%), therefore urgent measures are not necessary. Complete examination and control of dynamics of the portrait to prevent possible relapse of aggravation of symptoms are expedient.**

Thus, in spite of the fact that the device does not diagnose, accurate analysis of output data makes it possible to form reliable hypotheses even in screening estimation and take them in account in diagnosis in subsequent clinicoinstrumental examination.

The following example illustrates high sensitivity of the device to myocardial ischemia.

5 Patient 5. Diagnosis: IHD.

CardioVisor-06c output data: **Myocardium** : 16%, Pulse – 68. Horizontal position of electric axis. ECG: norm.

General conclusion: Moderate changes. Control of dynamics is expedient. **Ventricles:** Small changes. Complete examination is expedient as such changes can correlate with coronary vascular atherosclerosis.

The **portrait of the heart** there are typical changes in region 15 in the left ventricle which is evidence of ischemic changes (Fig. 11).

COMMENTS: Though the sight of the portrait resembles a normal heart the expressed redness in region 15 in the left ventricle, high indicator “Myocardium” and message about possible affected vessels are evidence of probable ischemic changes. If these symptoms are elicited for the first time complete examination and control of dynamics of the heart portrait are expedient.

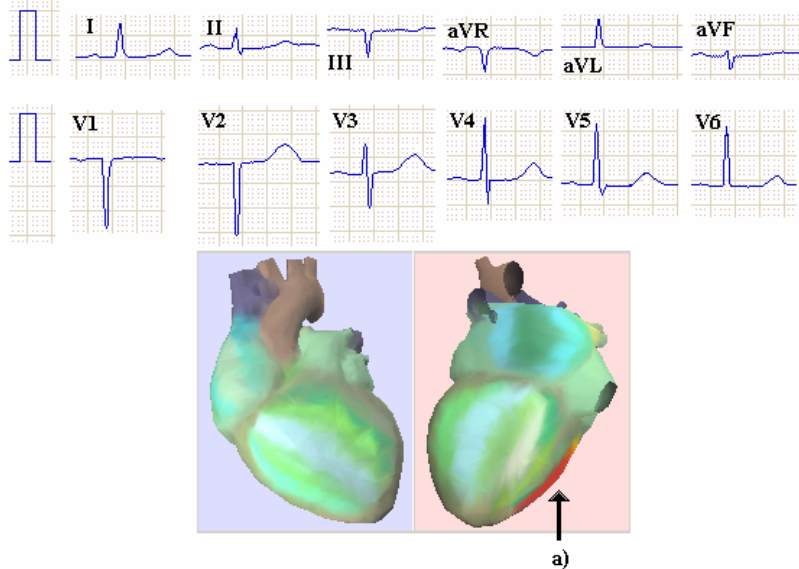


Fig. 11. Example of manifestation of ischemic changes in heart portrait with normal ECG.

a) - specific sign of myocardial

4.2. Reproducibility of output data of device

Reproducibility of output data was checked at the examinations of more than 130 patients in conditions of usual life activity (in sitting position). The device is of high reproducibility and stability to artifacts of ECG signal arising from bad contact of electrodes with the surface of the skin. With a stable state of the myocardium the portrait and text conclusions in successive examinations practically do not change.

An example of recurrence of portraits with pathology is given in Fig.12. Recurrence of dispersion characteristics of low amplitude fluctuations even in a healthy heart is not ideal as in each cardiocycle conditions of excitation periodically undergo small alterations (breathing, changing diaphragm position, local fluctuations of metabolic processes and other factors). Experimental data testify that **the highest recurrence of dispersion characteristics of low amplitude of ECG signal is observed in the group of people with verified diagnosis “norm”**.

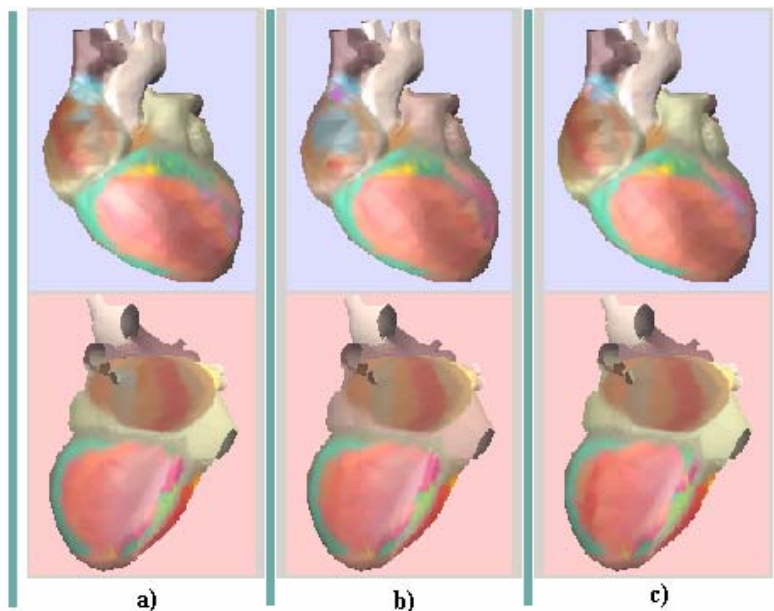


Fig .12. Reproducibility of pathological heart portrait with stable state of myocardium.

a) - first portrait, b) - 10 minutes later c) - one day later

In this group indicator “Myocardium” varies only in the range 0...15%, variations in successive examinations do not exceed 4%, while alterations in the portraits are so insignificant that they practically do not change the color of the “quasi-epicardium”.

4.3. Peculiarities of using the device for dynamics control

Due to high sensitivity the device has unique facilities for objective control of dynamics of myocardial changes. Dynamics control function can be used both for operative control of the reaction of the heart to the therapy and for highly precise control of dynamics of the state of the myocardium for months and years.

Information about changes in depolarization processes of the myocardium is seen right in the portrait of

the heart. Alterations in color and area of pathological foci in the “quasi-epicardium testify to the earliest stable changes in the state of the myocardium. Dispersion characteristics measured by the device reflect not only organic but functional characteristics.

This property allows the doctor to see pre-threshold dynamics which is not manifested by data of other diagnostic methods.

An example of pre-threshold dynamics of portraits is given in Fig. 13. This example corresponds to the following diagnosis: AG, expressed metabolic deviations - hypokalemia. ECG: sinus bradycardia, deviation of the electric axis to the left, signs of LA and LV enlargement. X-ray – rotation of the heart.

This Fig. shows four portraits registered in a patient in one and same time four days running. In a simultaneously taken ECG no dynamics was observed. At the same time ECG dispersion characteristics varied appreciably. The second portrait showed fewer color deviations (smaller area of red foci), while in the portraits obtained on the 3rd and 4th days deviations enlarge again (appearance of expressed red foci in both ventricles).

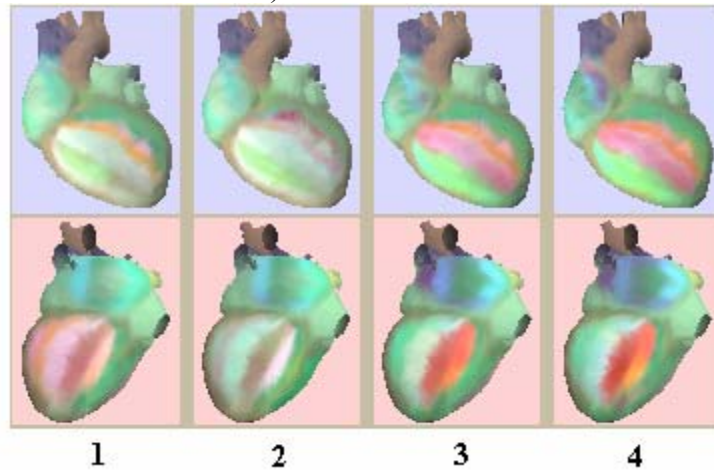


Fig. 13. Pre-threshold dynamics of state which is not manifested in ECG.

Registration of portraits in four days running.

5. Effectiveness of using the device

The characteristics of CardioVisor –06c considerably excel those of analogues intended for ECG screening. Suffice it to say that the time of obtaining the conclusion is 1...3 minutes, control is made without taking off clothes in the sitting position and indexes of sensitivity and specificity to ischemic heart disease increase to 80%. For comparison: mean ECG-12 sensitivity to IHD is only 30...40%. The latter means that more than 60% of occult or pre-clinic forms of developing ischemic heart disease at present are not elicited by methods of standard ECG analysis and require applying other expensive methods of investigation (CAG, myocardial scintigraphy, etc.).

5.1 Methods of estimating sensitivity and specificity in differentiation of NORM and PATHOLOGY

Sensitivity and specificity of CardioVisor-06c to differentiation of norm and pathology were estimated with the above strictly verified sample of 192 patients. The group of patients with pathological changes contained 171 examinations. This group included: 17 cases of IHD without scar change, 41 cases with scar changes, 12 cases of IHD against the background of LVH, 25 cases of intraventricular blockades, 9 cases of IHD after ACS and transplantation, 13 cases of LVH and aortomitral failures, 7 cases of LVH against the background of endocrinometabolic changes, 4 cases of hypertrophic cardiomyopathy, and 18 cases of combined ventricular hypertrophy (congenital and acquired heart diseases). The control group without clinically significant deviations (norm group) contained 21 examinations.

CardioVisor-06c responds not only to expressed pathological changes but to slightly expressed deviations

from the norm. Therefore when calculating sensitivity and specificity statistic indexes, correct monitoring of slightly expressed deviations is necessary. This monitoring was made on the basis of the idea of introducing intermediate degrees of pathology expressiveness into the estimation scale [6]. A scale of five gradations of the positive conclusion was used : D1 – expressed degree of pathology, D2 – low degree of pathology expressiveness, D3 – average degree of pathology expressiveness, D4 – slightly expressed pathological changes and D5 – absence of changes (norm). The classifier of the device is set to probability values of clinically significant pathology for each of these gradations: D1→ probability of clinically significant pathology is equal to 1.0, D2 → probability of clinically significant pathology is equal to 0.8, D3 → probability of clinically significant pathology is equal to 0.5, D4 → probability of clinically significant pathology is equal to 0.3, D5 → probability of clinically significant pathology is equal to 0. These five gradations of the positive result correspond with five opposite gradations of negative result : U1...5; U1 – obvious norm (no deviations), U2 – slightly expressed deviations from the norm, U3 – average degree of deviations from the norm, U4 – high degree of deviations from the norm and U5 – obvious absence of the norm (expressed pathology). As U1...U5 are opposite to positive events D5...D1, values of probability of pathological changes are set as: U1→ 1.0, U2→ 1.0-0.3=0.7, U3→1.0-0.5=0.5, U4→1.0-0.8=0.2, U5→0.

Sensitivity is calculated by formula:

$$Sens = \frac{PD1 \cdot 1.0 + PD2 \cdot 0.8 + PD3 \cdot 0.5 + PD4 \cdot 0.3}{PD1 + PD2 + PD3 + PD4 + FU} \cdot 100\%,$$

where PD1 - number of positive conclusions type D1 in patients (with pathology),

PD2 - number of positive conclusions type D2 in patients,

PD3 - number of positive conclusions type D3 in patients,

PD4 - number of positive conclusions type D4 in patients,

FU - number of negative conclusions type D5 in patients,

This formula differs from the standard

$$Sens = \frac{PD}{PD + FU} \cdot 100\%$$
 as the number of positive conclusions PD is substituted for the sum of all different states D1...D4 with weight coefficients determined by the classifier of the device.

Accordingly, specificity is calculated by formula :

$$Spec = \frac{PU1 \cdot 1.0 + PU2 \cdot 0.7 + PU3 \cdot 0.5 + PU4 \cdot 0.2}{PU1 + PU2 + PU3 + PU4 + FD} \cdot 100\%$$

where PU1 - number of negative conclusions type U1 in healthy individuals (with clinic diagnosis "norm"),

PU2 - number of negative conclusions type U2 in healthy individuals ,

PU3 - number of negative conclusions type U3 in healthy individuals,

PD4 - number of negative conclusions type U4 in healthy individuals,

FD - number of positive conclusions type U5 in healthy individuals.

5.2. Results of estimating sensitivity and specificity in differentiation of NORM – PATHOLOGY

$$PD1 = 159, PD2 = 5, PD3 = 2, PD4 = 3, FU = 2.$$

$$PD1 + PD2 + PD3 + PD4 + FU = 171.$$

$$Sens = \frac{159 \cdot 1.0 + 5 \cdot 0.8 + 2 \cdot 0.5 + 3 \cdot 0.3}{171} \cdot 100\% = \frac{164.9}{171} \cdot 100\% \approx 96\%.$$

$$PU1 = 15, PU2 = 4, PU3 = 2, PU4 = 0, FD = 0.$$

$$PU1 + PU2 + PU3 + PU4 + FD = 21.$$

$$Spec = \frac{15 \cdot 1.0 + 4 \cdot 0.7 + 2 \cdot 0.5}{21} \cdot 100\% = \frac{18.8}{21} \cdot 100\% \approx 90\%.$$

Thus sensitivity and specificity in differentiation of norm and pathology are 96% and 90% respectively. Two cases correspond to pseudo-negative conclusions ($FU=2$) in patients' group: the first – after successful angioplasty and the second – a year after successful ACS operation. Similarly, two pseudo-positive conclusions ($PU3 = 2$) in the group of healthy individuals are most likely caused by the absence of data of a more profound clinicoinstrumental examination which could elicit dispersion deviations.

5.3 Results of estimating sensitivity and specificity in differentiation of myocardial ischemia

Sensitivity and specificity only to ischemic changes were estimated on a sample of 87 patients with diagnosis IHD and 50 patients without IHD. The control group of patients without IHD included 10 healthy individuals, 20 cases of HLV in patients with heart diseases and AG, 20 cases of combined hypertrophy. The age of the patients varied from 27 to 72 years (mean age – 53 ± 5.2 years). The results of estimation of sensitivity of the device to myocardial ischemia by subgroups of patients is given in *Table 1*.

Table 1

№ №	Name of pathology subgroup	PD1	PD2	PD3	PD4	FU	Sens
1	IHD without scars	1	2	3	2	1	52%
2	IHD with scar changes	13	3	0	0	0	96%
3	IHD against LVH background	1	8	2	1	0	73%
4	Intraventricular blocks	10	1	0	0	0	98%
5	Auricular fibrillation	1	1	1	0	0	77%
6	IHD after ACS and transplant	22	5	8	1	0	80%

Mean sensitivity *Sens* to ischemia in the sample of 87 cases of verified IHD was

$$Sens = \frac{52 + 96 + 73 + 98 + 77 + 80}{6} \approx 80\%.$$

The results of estimation of specificity to myocardial ischemia by subgroups of patients are given in Table 2.

Table 2

№ №	Name of pathology subgroup	PU1	PU2	PU3	PU4	FD	Spec
1	Norm	10	0	0	0	0	100%
2	LV hypertrophy (aortomitral diseases and AG	8	2	3	0	0	76%
3	LV hypertrophy against background of endocrino-metabolic changes	1	0	3	1	2	39%
4	Hypertrophic cardiomyopathy	0	1	1	0	0	60%
5	Combined ventricular hypertrophy (congenital and acquired heart diseases)	4	2	4	3	5	39%

Mean specificity *Spec* to ischemia in the sample of 50 cases of verified absence of IHD was

$$Spec = \frac{100 + 76 + 39 + 60 + 39}{5} \approx 63\%.$$

Thus, in estimating effectiveness the device confirmed the following characteristics :

Sensitivity to pathological changes	not lower than 95% (out of which sensitivity to early signs of ischemia not lower than 80%)
Specificity to pathological changes	not lower than 90% (out of which specificity to early signs of ischemia not lower than 63%)
Examination duration	not longer than 3 min., including applying electrodes
Ergonomic properties of program interface	Application of device involves no technological or psychological discomfort
Output data	<ul style="list-style-type: none"> • Heart portrait (right and left views of epicardium with outlined pathological changes) • Integral indicator of pathological myocardial changes • List of probable pathologies • Recommendations for doctor

The estimation of effectiveness also confirmed the authenticity of calculation of integral indicator “*Myocardium*”. The value of this indicator – 15% effectively determines the norm or slightly expressed deviations from clinically significant pathological changes within the limits of guaranteed sensitivity.

Conclusions :

1. The estimation of effectiveness of CardioVisor-06c has shown that it is suitable for screening examinations in terms of authenticity and quickness of obtaining a screening conclusion.

2. CardioVisor-06c has high sensitivity and specificity (80 % and 63% respectively) to be used in elicitation of IHD.
3. CardioVisor-06c provides new facilities for highly sensitive control of dynamics of myocardial changes which due to simplicity and short-time procedure can be effectively used in the practical work of a doctor.

6. Possible errors

CardioVisor – 06c shows high interference immunity in automatic analysis of dispersion changes in ECG signal and formation of a portrait of the heart. The main and practically the only source of rare hypersensitivity of the device can be ECG signal artifacts caused by muscular tremor. Absolutely still state of the patient when applying ECG removes this rare effect.

If fluctuations of isoelectric line at the ECG input exceed 2 mV, the device gives information about impossibility of forming a dispersion portrait of the heart. Minor fluctuations of the iso-line short-time artifacts do not affect the quality of the portrait.

7. The place ECG DP among other functional methods

CardioVisor-06c using the ECG DP method do not diagnose, therefore it is incorrect to compare it with instruments and tests intended for diagnosis. However, the given instrument considerably excels the existing instruments and tests for screening examinations in authenticity and effectiveness of eliciting pathologies. Within 2 minutes this instrument can reveal many pathologies at the pre-clinic stage with a 95%-sensitivity to differentiation of norm/pathology states. Besides, this is the only instrument which makes it possible to non-invasively

and quickly exercise highly sensitive control of the earliest functional changes as well as detect ischemic myocardial changes with a 90%-sensitivity and a 63%-specificity.

Reference

1. Patent DE 198 01 240: Soula A., Gillessen W., Kitashine Y. Verfahren und Vorrichtung zur Darstellung und Überwachung von Funktionsparametern eines physiologischen Systems, 1999.
2. Patent DE 199 33 277: Soula A., Gillessen W., Kitashine Y. Verfahren und Vorrichtung zur visuellen Darstellung und Überwachung Physiologischer Funktionsparameter, 2001.
3. Tompson G.M.T. Instability and catastrophes in science and technology Translated from Eng. into Rus. – M.; Mir , 1985, pp. 254
4. Galen C. Wagner Practical electrocardiography by Marriott , translated from Eng.- SPb Nevsky Dialect; M.: Publishing House BINOM, 2002 pp.480, in Russian
5. Deedwania P. Pepine C.J. Cohen P et al. The monitoring increase in myocardial ischemia is effectively suppressed by atenolol, //Circulation. 1993. V.88 P.1594
6. Bulygin V.P., Koltsun S.S., Fedorodva S.I., Chepaikin A.G., Shumsky V.I. Improved methods of tests of medical interpreting instruments.// Functional diagnosis, 2003 # 1, pp.93-100, in Russian.